TBL-2
NEU Block

Q1. A patient resuscitated from cardiac arrest for more than a few minutes had no recollection of the events that preceded the cardiac arrest and was unable to recall events some hours after being resuscitated. Which structure of the brain was affected?

A. Dorsolateral Premotor Cortex
B. Orbitofrontal Cortex
C. Hippocampus
D. Amygdala
E. Basal Ganglia

Ans: C

Q2. Addiction is characterized by reduced activation in which part of the brain?

A. Ventral tegmental area
B. Nucleus accumbens
C. Caudate
D. Putamen
E. Frontal

Ans: E

Q3. A 44- year old man complained to his physician of burning and tickling in his hands and feet. The man was diagnosed with tonic-clonic seizures three years ago and has been receiving high dose of anti-seizure drug since then. Physical examination disclosed large inguinal lymph nodes and reflex testing showed lack of knee and ankle tendon reflexes. Further lab exams showed megaloblastic anemia. Which of the following drugs most likely caused the patients symptoms and signs?

A. Tiagabine
B. Gabapentin
C. Lamotrigine
D. Phenytoin
E. Clonazepam

Ans: D

Q4. A patient is prescribed alprazolam to treat her panic disorder. Binding at which site produces the drug's action?

A) Melatonin receptor
B) GABA -a receptors at the interfere with **α** and γ 2 subunits
C) 5-HT 1D receptors
D) Opioid μ receptors
E) Histamine H1 receptors

Ans: B

Q5. A 56-year-old woman presented with the acute onset of weakness of her left side. An MRI showed multiple areas of restricted diffusion in the right frontal lobe. An EKG showed atrial fibrillation. Which of the following medications should be used to minimize her risk of another stroke?

A. Intravenous heparin
B. Aspirin
C. Warfarin
D. Clopidogrel
E. Tissue plasminogen activator

Ans: C

Q6. Which of the following seizures occur as a result of hyperventilation?

A. Generalized tonic-clonic
B. Generalized myoclonic
C. Generalized tonic seizure
D. Absence seizure

Answer: D

Q7. A 58 year old woman was driving her car when she had the sudden onset of a severe headache. She pulled into a service station and stopped the car. Then, she slumped over the wheel. She was taken to the emergency room where she remained comatose and died hours later. The gross appearance of her brain found at autopsy is attached. Which of the following is the most likely diagnosis?

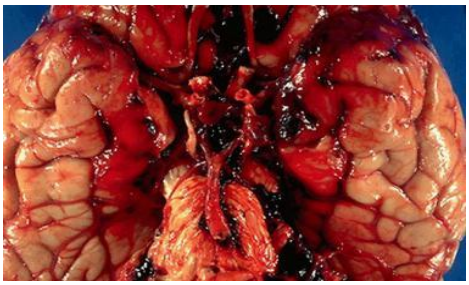

A. Thrombotic brain infarct

B. Embolic brain infarct
C. Rupture of AV malformation
D. Epidural hemorrhage
E. Ruptured berry aneurysm

Ans: E

Q8. A 62-year old man is undergoing hip joint replacement. During this procedure the anesthesiologist reports a drop in blood pressure for 30 minutes despite intervention with pressor agents. Which of the following pathologic lesions is most likely to occur in his brain as a consequence of this prolonged hypotensive episode?

A. Frontal lobar hemorrhage
B. Lacunar infarct in corpus striatum
C. Hemorrhagic infarct in brain parenchyma
D. Embolic infarct in parietal lobe
E. Linear parasagittal infarction

Ans: E

Q9. A 50-year-old male was recently diagnosed with moderate Parkinson's disease that is interfering with his daily life. In which of the following situations you would choose to start levo-dopa therapy rather than dopamine agonists?

A. Personal history of alcohol abuse
B. Family history of hypertension
C. Personal history of cigarette smoking
D. Personal history of type 2 diabetes mellitus

Ans: A

Q10. Comparing levo-dopa therapy with dopamine agonist therapy for the management of parkinsons disease, which of the following side effects are more pronounced with dopamine agoinst?

A. Nausia and anorexia
B. Postural hypotension
C. Anxiety and depression
D. Tachycardia
E. dyskinesia

Ans: C

Q11. Which of the following is the most effective treatment for Panic disorders?

A. Psychodynamic psychotherapy
B. Cognitive behavioral therapy
C. Tricyclic antidepressants
D. Benzodiazepines
E. Combination of psychotherapy and pharamacotherapy

Ans: E

Q12. Which of the following is characteristic of bipolar disorder II?

A. hypomania plus mania
B. depression only
C. hypomania and depression
D. mania and depression
E. mania and psychosis

Ans: C

Q13. A 30-year-old woman present with blurry and dim vision in the right eye and paresthesias, especially involving the left lower limb. She says that she has had occasional bouts of fatigue and poor vision over the past few years as well as occasional muscle weakness. She has no decrease in mentation. Her CSF analysis revealed elevated levels of IgG, some mononuclear cells, and oligoclonal bands on gel electrophoresis. Which of the following pathologic findings in the CNS is she most likely to have?

A. Loss of pigmented neurons in the substantia niagra.
B. Increased neurofibrillary tangles and neuritis plaques in the neocortex.
C. Perivascular lymphocytes with demyelinated axons in white matter.
D. Gliosis with atrophy of caudate and putamen
E. Foci of multinucleated cells and macrophages in grey and white matter.

Ans: C

Q14. A 64 year old chronic alcoholic man presented to his physician with confusion, eye movement abnormalities, staggering gate and confab confabulation. Which is following structures are the most likely involved in the pathogenesis of this disorder?

A. Mammillary body, hippocampus and third nerve Nucleus
B. Thalamus, hippocampus, and sixth nerve Nucleus
C. Mammillary body and third and seventh nerve nuclei
D. Mammillary body, hippocampus and third nerve Nucleus
E. Mammillary body, thalamus and third nerve nucleus

Ans: E

Q15. A 70-year old man developed stopped posture, masked facies, shuffling gait and pill rolling tremor in the right hand. Increased tonic discharge from which of the following structures is the cause of these symptoms ?

A. Dentate nucleus
B. Globus pallidus interna
C. Putamen
D. Caudate nucleus
E. Thalamus

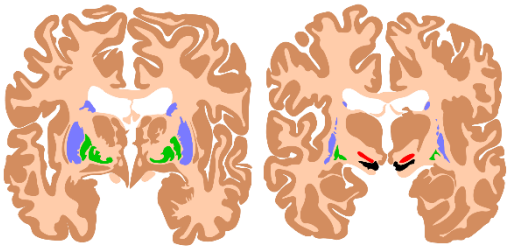

Ans: B

Q16. An infarction in the structure shown in red (see attached figure) will result in?

A. Parkinson's disease
B. Huntington's disease
C. Hemiballismus
D. Creutzfeldt Jakob disease
E. Alzheimer disease

Ans: C

Q17. A 60-year-old man heavy drinker has steadily worsened over the past months. He noticed that he now needed to stand with his feet far apart in order to maintain his balance and that he waddled when he walked. He has past pointing and dysdiodochockinesis on neurological examination. Which one of the following nuclei is involved in this case?

A. Vestibular nuclei
B. Dentate nucleus
C. Caudate nucleus
D. Lentiform nucleus
E. Nucleus fastigi

Ans: B

Q18. A 10-year-old child fell from the roof top and MRI of the brain showed ischemia of bilateral temporal lobes due to extensive hemorrhages. Which one of the following behavioural changes is expected in this patient?

A. Docility
B. Excessive Anger
C. Excessive Fear
D. Excessive Sleepiness
E. Excessive Happiness

Ans: A

Q19. After reviewing Mr Tomas CT scan, the neurologist has advised the following cognitive test. Based on the patient presented symptomatology (see the attached picture) Which one of the following tests would you advise?

A. Wisconsin's sorting task.
B. Copy the picture
C. Go-No-Go task
D. False-Belief task
E. Word association task

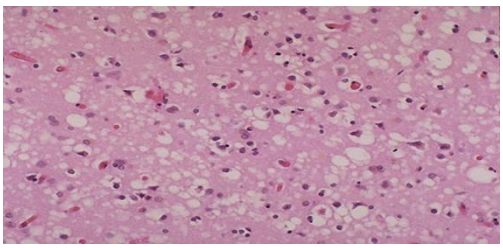

Ans: B

Q20. A 70 year old previously healthy woman has become more forgetful over a period of 6 weeks. Two months later, she has difficulty ambulating, stops talking and is unable to care for herself. On physical and mental examinations, she has dementia, ataxia, myoclonus, and mutism. She is afebrile. CT scan of the head shows minimal cerebral atrophy. An EEG shows slow waves with spikes. Over a period of next two weeks, she deteriorates, goes into coma, and dies. Microscopic picture of the representative cortical area of her brain is shown below. Which of the following is the most likely diagnosis?

A. Creutzfeldt-Jakob disease
B. Alzheimer disease
C. HIV encephalitis
D. Pick disease
E. Variant Creutzfeldt-Jakob disease

Ans: A

Q21. A 40-year-old man presents with involuntary facial grimaces, twitching movements of the fingers and jerky movements of distal parts of lower limbs. His mother had had similar symptoms beginning at about the same age. Her disorder had progressed to dancing movements, writhing of the arms and legs, and eventually coma and death over a period of about 15 years. His maternal grandfather had had a similar disorder but at an age older than the mother. Which of the following is most characteristic of this disease?

A. Degeneration of upper and lower motor neurons
B. Dopamine depletion and depigmentation of the substantia nigra
C. Neurofibrillary tangles and amyloid plaques in the cerebral cortex
D. Increased number of trinucleotide repeats in a gene on chromosome 4
E. Pick bodies, characterized by round intracytoplasmic inclusions consisting of neurofilaments

Ans: D

Collected by:
10th Batch Exam Committee
Good Luck :)